Archives of Aesthetic Plastic Surgery
Vol. 19, No. 2, 95-100, 2013

A Revisional Malarplasty: Endoscopic Zygoma Reduction (EZ technique)

Jung Soo Lee, M.D.

Youtiful Vom Plastic Surgery, Seoul, Korea

The reduction malarplasty is becoming prevalent among Asians due to their characteristics of protruding cheekbones. As the cheekbone protrusion is known among the Asians as a feature which gives strong and perhaps a negative impression, people nowadays are relying more on the revisional reduction malarplasty for a symmetrical facial line. At Youtiful Vom Plastic Surgery, eleven cases of malar reduction were performed using the endoscopic zygomatic arch infracture technique (EZ technique) from January to May of 2013. Then, eight patients of the eleven completed a survey based on their level of satisfaction of the surgical process. When performing the surgery, we made a temporal incision and used the endoscopic application to open up the area malar prominence and the previously osteotomy line. We then made a complete osteotomy on the zygomatic arch after making the incomplete osteotomy on the zygomatic body. The surgery was completed after finally infracturing the fragmented segment with a mallet in a greenstick fracture. After the surgical performance, we surveyed the patients regarding their level of satisfaction of the surgery, the anesthesia used during surgery, the recovery period, and the postoperative pain all out of a scale from 1 to 5. Based on our results, the level of satisfaction in terms of the patients' surgical results accounted for 4 out of 5 and a 4.3 out of 5 for the level of satisfaction of patients in terms of the anesthesia used during surgery. Thus, the patients achieved a high level of satisfaction. Like so, the EZ technique is an effective and simple revisional method that can be used to correct the protrusion of the zygomatic arch with also a relatively quick recovery period.

(Arch Aesthetic Plast Surg 19: 95, 2013)

Key Words: Zygoma, Reduction, Endoscopy, Greenstick

I. INTRODUCTION

One of the main characteristics of the face of an Asian is mesocephaly, a term meaning protruded cheekbones and wide mandibles. The cheekbone of the midface plays an important role in giving an attractive facial contour. For Westerners, lateral protrusion and malar eminence is recognized as one of the essential factors to consider when defining beauty. However, it is likely that this is not the case for Asians since protruded cheekbones are said to give a strong impression and make the face look larger.

In the past, patients with large cheekobones including zygomatic body and arch were the majority who desired to undergo reduction malarplasty. However, the number of patients who wish to take surgery with even the slightest protrusion of the cheekbones are gradually increasing.

At the author's clinic, patients with a protrusion of the zygomatic body and arch underwent surgery with the technique of the L-shaped complete osteotomy on the zygomatic body and a complete osteotomy on the zygomatic arch with a temporal incision. Patients with a protruded zygomatic arch and a normal zygomatic body were operated with the Endoscopic Zygomatic

Received June 14, 2013
Revised June 16, 2013
Accepted June 17, 2013

Address Correspondence: Jung Soo Lee, Youtiful Vom Plastic Surgery, 4th floor Daedong Tower, 93 Nonhyun-dong, Gangnam-gu, Seoul, Korea
Tel: +82-2-545-3700, Fax: +82-2-545-0475, E-mail: bomps@naver.com

*This work was presented at the 31st Congress of the Korean Society for Aesthetic Plastic Surgery in Seoul, Korea, April 27, 2013.

이정수 약력

고려대학교 의과대학 졸업
고려대학교 의학대학원 박사
이대 목동병원 성형외과 수료
유티플 봄 성형외과 대표 원장

arch infracture technique (EZ technique.) The use of this endoscopic technique is increasing.

If we look at the cases for revisional reduction malarplasty for example, we see that patients underwent further surgery, even after the completion of their previous malarplasty, to reform and correct the lateral line for a smoother facial contour.

As of January to May in 2013, there were twelve cases of patients who desired revisional reduction malarplasty due to unsatisfactory results from their previous malarplasty. In most of the cases, a slight protrusion of the zygomatic arch still remained. Eleven out of the twelve cases of the correction of this protrusion was possible through the EZ technique. Eight cases of the patients were surveyed based on their level of satisfaction. This paper will present the indications and usefulness of this technique.

II. MATERIALS AND METHODS

A. Patients

From January to May in 2013, we have undergone the EZ technique for eleven patients who desired revisional reduction malarplasty. The whole process including their follow-up period accounted for ten weeks while the average age of the patients was 29.1 years old, all of them being female.

A line from the meeting point of the frontal process of the zygomatic bone and the temporal process of the zygomatic bone to the inferior margin of the zygomaticomaxillary suture was made. We call this line the "Eminence line" (E-line). The "Eminence zone" (E-zone) is defined as the area with a width of 5mm from both anterior and posterior sides from the E-line (Fig. 1). The E-zone is the area of a total distance of 10mm from the anterior to the posterior margin which we use to perform the anterior osteotomy within the boundary of the margin. However, it is important to note that this does not always apply in the cases of revisional surgeries.

We were able to apply the EZ technique to eleven patients with lateral prominence of the zygomatic arch.

B. Operative Procedure

The endoscopic zygoma reduction surgery was performed to eleven cases who wanted to revise their arch prominence after they have previously undergone reduction malarplasty.

Nine cases were operated under sedative anesthesia and two cases were done with mandibular contouring surgery under general anesthesia. A CT scan had to be taken before surgery and a careful check of the positioning and the state of union of the previous osteotomy line had to be done.

An incision was placed behind the temporal hairline and

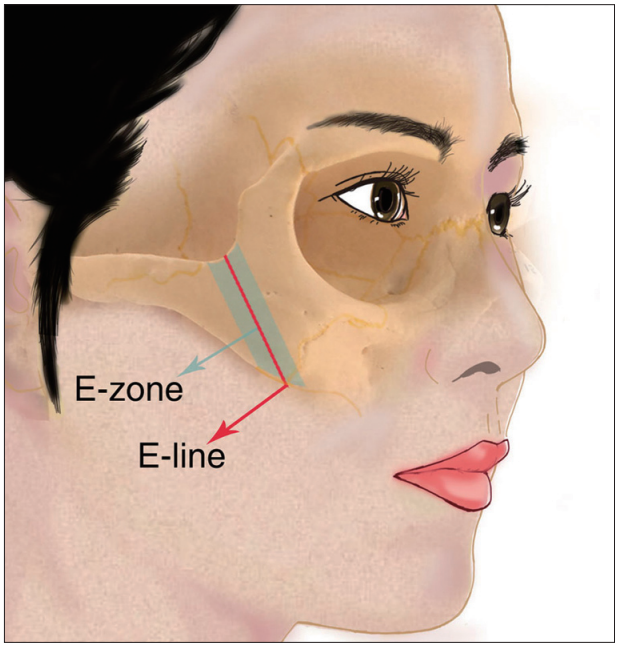

Fig. 1. Eminence line and Eminence zone.

dissection was made down through the temporoparietal fascia to the level of the temporalis fascia. Dissection was continued in this plane between the temporoparietal fascia and the temporalis fascia down to the superior junction of the zygomatic arch and frontal process of zygomatic bone and to the inferior border of the zygomaticomaxillary suture under the vision of an endoscope.

During dissection, the fixation devices such as the plate or the wire on the previously fixated area had to be checked. An incomplete anterior osteotomy was made on the lateral side of the previously fixated devices. Only in one out of the eleven cases the osteotomy on the medial side was performed.

Another incision was then made in the superficial layer of the temporalis fascia at the same incision site, and a blunt dissection was performed to the zygomatic arch in front of the articular tubercle. The periosteum of the inner side of the arch was elevated.

A complete posterior osteotomy was then performed in front of the articular tubercle with the direction toward the posterolateral side. After this was done, the mobility of the bone fragment needed to be checked using finger pressure. Finally, we infractured the osteotomized segment using the force of a mallet. The fractured fragment was maintained stably in shape of a Z.

C. Satisfaction Survey

We asked eight of the eleven patients who went through to the follow-up to complete a survey based on their level of satisfaction after surgery. The questions of the survey were as follows

1) If you had to rate your level of satisfaction of the surgery, how much would you rate it out of a scale of 1 to 5? (5 being the highest, 1 being the lowest)

2) How would you rate your level of satisfaction in terms of the recovery period?

3) How would you rate your level of satisfaction in terms of the type of anesthesia used during surgery?

4) How would you rate your level of satisfaction in terms of the postoperative pain?

III. RESULTS

Six of the eleven cases performed were for the purpose of the correction of asymmetry and the remaining five were for the reduction of zygomatic arch protrusion. Two cases of primary reduction malarplasty were undergone in Youtiful Vom Plastic Surgery and the remaining nine cases were undergone from other clinics. Five cases of the correction of asymmetry were completed with unilateral osteotomy, and one of the cases was performed with bilateral osteotomy.

Eight of the eleven patients were able to take the follow-up, and these patients had the highest level of satisfaction as shown in Table I and II.

Fig. 2 depicts the case underwent revisional reduction malarplasty with EZ technique. A 29 years aged female patient complained a mild malar prominence of the arch portion. Under the endoscopic field, a bony defect was found on the upper margin of right zygomatic arch, 11.1 mm length and 4.5mm on the widest portion which was filled with fibrous tissue. A fixation device was wire and osseous union state was visible. On the left zygomatic arch, a bony defect was found, which was 15. 1 mm in length and 5.2 mm on the widest portion. We performed anterior incomplete osteotomies on the previous osteotomy line, posterior complete osteotomies in front of the articular tubercle to infracture the zygomatic arch.

Another case of revisional reduction malarplasty with EZ technique is 36 female patient who complained under correction even though she had undergone reduction malarplasty through the intraoral approach. Under the endoscopic field, a fibrous union stated anterior osteotomy line were visible on both sides. Only posterior osteotomies could made the malar prominences to be reduced (Fig. 3).

IV. DISCUSSION

The rapid increase of the cosmetic surgery today proves to us that beauty plays an essential role in our society. The concept of beauty asset may be considered as an additional personal asset for some and it is true that people in this society are willing to refine their facial appearance more than ever. Hakim[3] introduces a new theory,"Erotic capital," as the fourth personal asset which is an important addition to economic, cultural, and social capital. Hence, an attractive appearance with a healthy-shaped body may be considered as the hidden factor for change of social status and occupational success among women.

The facial appearance plays an important role in determining physical attractiveness. The zygoma is located on the central part of face, which is a very important area of the face as it is also the area where it connects other facial bones. According to Naini[4] one of the most recognizable features of the midface is the contour and prominence of the superior-lateral part of the

Table II. Satisfaction Summary

Provision	Average
Satisfaction	4/5
Anesthesia	4.3/5
Post-operative Pain	3.5/5
Recovery periods	3.8/5
Total	3.9/5

Table I. Postoperative Evaluation

Case No.	Age & Sex	Purpose	Recovery periods (days)	Postoperative Evaluation				
				Satisfaction	Anesthesia	Post-operative Pain	Recovery periods	Remark
1	30/F	Reduction	10	4	4	3	4	Plate
2	23/F	Reduction	14	3	4	2	3	Wire
3	26/F	Reduction	10	4	5	2	3	Plate
4	36/F	Asymmetry	7	5	5	4	5	Wire
5	26/F	Reduction	10	3	3	3	3	Plate
6	25/F	Reduction	10	4	5	5	4	Wire
7	33/F	Asymmetry	7	5	5	5	5	Wire
8	36/F	Asymmetry	14	4	4	4	4	None

cheek, termed the malar eminence formed by the underlying zygomatic bone.

However, the facial contour of an Asian's is different. Asians with mesochephaly tend to have protruded cheekbones and may give the patient a strong impression and make the face look bigger.

The increasing technology today, especially with the growing number of smart phone users, could be one of the causes of the increase in reduction malarplasty, as people have the ease to compare each other's appearance through various social networks. Thus, the number of patients wanting to take revisional malarplasty for correcting asymmetry of the cheekbones or

(A) (B)

Fig. 2. 29 years aged female patient. Complaint is mild protruded malar eminence even though patient had previously undergone reduction malarplasty. Previously fixated devices are wires. Bilateral anterior and posterior osteotomy is done (Right side). She also underwent mandibular contouring, endobrow lift and eyelid surgery. (A) Preoperative (Left, upper) and Postoperative (Right, upper) right side oblique view of CT scan. Preoperative (Left, lower) and Postoperative (Right, lower) left side oblique view of CT scan. White arrow is previous osteotomy line. Right is osseous union and left is fibrous union. Black arrow is new anterior and posterior osteotomy line. (B) Preoperative (Left) and Postoperative (Right) four weeks front views and worm's eye views.

(A) (B)

Fig. 3. 36 years aged female patient. Complaint is under correction. Only bilateral posterior osteotomy is done. (A) Preoperative (Left) and Postoperative (Right) CT scan. Black arrow is new osteotomy line. (B) Preoperative (Left) and Postoperative (Right) front views and worm's eye views.

reducing protrusion of even the slightest cheekbone is steadily increasing.

From 2011 to 2012, there were merely three patients who underwent revisional malarplasty using the EZ technique. The number of patients increased to eleven in the period of January to May in 2013. We see that the number of surgical cases of revisional malarplasty is increasing, but this also proves that the standard for beauty has changed among people as they want even the slightest, most detailed change in their faces even after their first surgery.

A majority of the reduction malarplasty is performed with the anterior osteotomy of the body of the zygomatic bone and posterior osteotomy of the zygomatic arch. The two methods mostly applied are: 1. Making a complete osteotomy on the anterior and posterior side and repositioning the fragmented zygoma or 2. Making an incomplete osteotomy on the anterior and a complete osteotomy on the zygomatic arch, in a greenstick fracture.[5-12]

We used the greenstick fracture technique through the endoscopic application which is a method proved to be useful for reducing scars and any damage on the skin[13-16]. This method also is useful not only in enlarging the view of the surgical area, but also undergoing surgery in a very short period of time. The endoscopic application does not cause cheek drooping, which is lead by the sagging of the soft tissue of the anterior part of the maxilla. There are multifactors that cause the cheeks to sag, and this can be seen only through the approach of intraoral reduction malarplasty after surgery. To perform the intraoral reduction malarplasty, one must reach the malar bone through subperiosteal dissection passing through the maxilla. This process may be the primary cause of cheek drooping. It is difficult for the dissected periosteum to move back to its original position after surgery. So, we can come up with the conclusion that the soft tissue like the buccal fat pad sags down, causing the anterior part of the maxilla to also look saggy. However, the EZ technique does not cause droopy cheeks since we do not perform the subperiosteal dissection on the maxilla as well as other muscle incisions.

It is crucial to determine where to make the anterior osteotomy line from checking the previous osteotomy line and the state of union of the bone.

We performed the anterior osteotomy medially or laterally to the previous osteotomy line in the state osseous union with strong fixation. In this case, the new osteotomy line becomes the pivot point (Fig. 4-A). There are cases where the plate fixation is loose. Here, the new osteotomy can be performed on the exact same place as where the previous osteotomy was done. The pivot point now is the osteotomy line (Fig. 4-B). A fibrous union through the CT scan can be found before surgery. We can then confirm the mobility of the fibrous union under the endoscopic field. Here, the infracture is possible through posterior osteotomy alone. Even if a new osteotomy can be made lateral to the previous osteotomy line, the previous osteotomy line becomes the pivot point.

Furthermore, when making a new anterior osteotomy, it is important not to make a complete incision. This is because the complete ostoetomy of the bone fragment can be moved down because of the masseter muscle.

It is also important to make an osteotomy on the posterior osteotomy in the posterolateral direction. The osteotomy must be done vertically within an angle of five degrees. After the greenstick fracture is completed, the bone fragment becomes the Z configuration. We can prevent the infractured bone segment from the recurrence caused by the masseter and tempo-

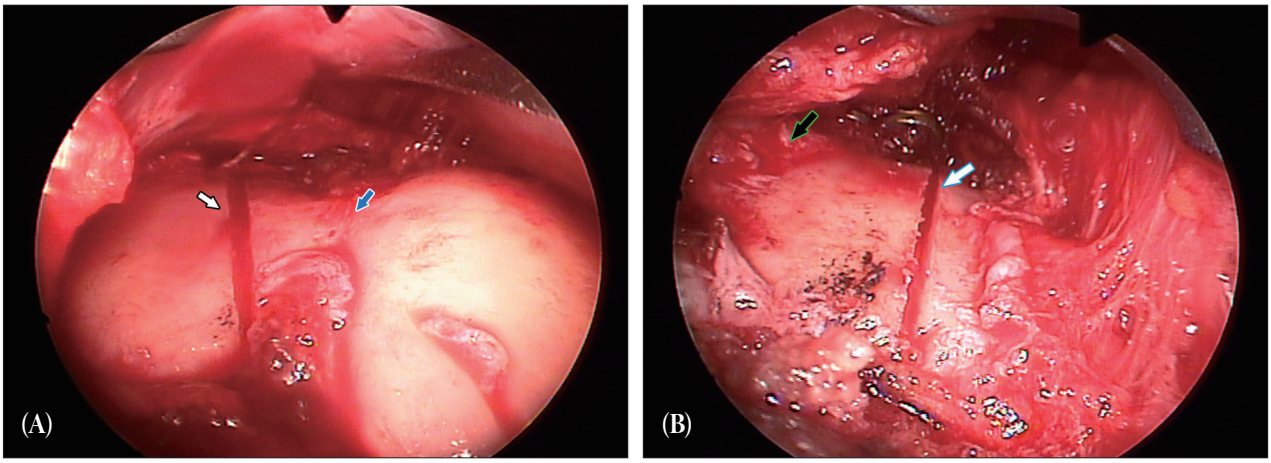

Fig. 4. Intraoperative endoscopic view. (A) Previous osteotomy line (blue arrow) is unioned by osseous union. So new osteotomy line (white arrow) become a new pivot point. (B) Previous osteotomy line (black arrow) is unioned by fibrous union. New osteotomy line (white arrow) is made but pivot point is previous osteotomy line.

ralis muscle to the original position.

As we can see from the results shown in table 1, the level of satisfaction was the highest among patients who underwent malarplasty for correction of asymmetric cases. Cheekbones tend to mostly be asymmetrical, and this is also the case for those who have already taken malarplasty. However, the results from table 1 illustrates that the problem of having asymmetrical cheekbones was solved. The type of anesthesia used was also a reason for high satisfaction among the patients. This is due to the absence of throat pains after surgery, which is also a factor of why patients are reluctant to undergo revisional cheekbone reduction.

V. CONCLUSION

There are various ways of the revisional malarplasty. We concluded that our method can be applied to patients who desire to correct the arch prominence on their cheekbones, asymmetric cases even though patients had previously undergone reduction malarplasty. The advantages of our technique are that the time of operation and the recovery period are relatively short, and can be performed under sedative anesthesia. The endoscopic application does not cause cheek drooping because of no subperiosteal dissection on the maxilla. Overall, patients can achieve a smooth attractive midface contour after our revisional malarplasty technique.

REFERENCES

1. McCurdy JA Jr., Lam SM: *Cosmetic surgery of the asian face*, 2nd ed, Thieme 2005, p 213
2. Lee JS, Kang SR, Kim YW: Endoscopically assisted malarplasty: one incision and two dissection planes. *Plast Reconstr Surg* 111(1): 461, 2003
3. Hakim C: Erotic capital. *Eur Sociol Rev* 26(5): 499, 2010
4. Naini FB: Facial aesthetics: *Concepts and clinical diagnosis*, Wiley-Blackwell 2011, p 238
5. Lee KC, Ha SU, Park JM, Kim SK, Park SH, Kim JH: Reduction malarplasty by 3-mm percutaneous osteotomy. *Aesthetic Plast Surg* 30: 333, 2006
6. Hwang YJ, Jeon JY, Lee MS: A simple method of reduction malarplasty. *Plast Reconstr Surg* 99(2): 348, 1997
7. Lee JG, Park YW: Intraoral approach for reduction malarplasty: a simple method. *Plast Reconstr Surg* 111(1): 453, 2003
8. Kim YH, Seul JH: Reduction malarplasty through an intraoral incision: a new method. *Plast Reconstr Surg* 106(7): 1514, 2000
9. Cho BC: Reduction malarplasty using osteotomy and repositioning of the malar complex : Clinical review and comparison of two techniques. *J Craniofac Surg* 14(3): 383, 2003
10. Onizuka T, Watanabe K, Takasu K, Keyama A: Reduction malar plasty. *Aesthetic Plast Surg* 7: 121, 1983
11. Sumiya N, Kondo S, Ito Y, Ozumi K, Otani K, Wako M: Reduction malarplasty. *Plast Reconstr Surg* 100(2): 461, 1997
12. Wang T, Gui L, Tang X, Liu J, Yu D, Peng Z, Song B, Song T, Niu F, Yu B: Reduction malarplasty with a new L-shaped osteotomy through an intraoral approach : Retrospective study of 418 cases. *Plast Reconstr Surg* 124(4): 1245, 2009
13. Pham AM, Strong EB: Endoscopic management of facial fractures. *Curr Opin Otolaryngol Head Neck Surg* 14: 234, 2006
14. Kim JW: Laser-assisted endoscopic reduction malarplasty in Asians: Quick combined surgery. *Aesthetic Plast Surg* 22: 289, 1998
15. Park DH, Lee JW, Song CH, Han DG, Ahn KY: Endoscopic application in aesthetic and reconstructive facial bone surgery. *Plast Reconstr Surg* 102(4): 1199, 1998
16. Kobayashi S, Sakai Y, Yamada A, Ohmori K: Approaching the zygoma with an endoscope. *J Craniofac Surg* 6(6): 519, 1995