ORIGINAL ARTICLE

https://doi.org/10.14730/aaps.2022.00514
Arch Aesthetic Plast Surg 2023;29(1):20-28
pISSN: 2234-0831 eISSN: 2288-9337

aaps
Archives of Aesthetic Plastic Surgery

Hybrid columellar strut using nasal crest bone of the maxilla and conchal cartilage for nasal tip stability in rhinoplasty for East Asian patients

Min Young Kim[1], Dong Il Kim[2], Jeong Hun Shin[2], Jin Woo Kim[1]

[1]Department of Plastic and Reconstructive Surgery, Inje University Busan Paik Hospital, Inje University College of Medicine, Busan, Korea
[2]Galaxy Plastic Surgery Clinic, Busan, Korea

The authors gratefully acknowledge Hyun Kim (Pinpoint Art Centre, Seoul, Korea) for the excellent medical illustrations.

Background Proper nasal tip projection and rotation are essential for an aesthetically pleasing nose. However, East Asians usually have thicker skin and underdeveloped nasal cartilage compared to Caucasians. Thus, techniques such as the septal extension graft, columellar strut graft, and L-shaped alloplastic implants have been introduced for additional nasal tip support and projection. However, no consensus exists regarding the optimal method.

Methods A hybrid columellar strut made of an osteochondral graft recombined with the nasal crest of the maxilla and conchal cartilage was devised. In a cadaveric study, changes due to an external bending force of the hybrid strut and costal cartilage in the same dimension were measured. In a comparative study, we divided 20 subjects into two groups according to the material used for the columellar strut graft: a hybrid columellar strut (experimental group) and a double-layered conchal columellar strut (control group). Preoperative, 1-month postoperative, and 1-year postoperative anthropometric measurements were compared between groups.

Results In the cadaveric study, the hybrid columellar strut showed superior mechanical strength. In the comparative study, the average 1-year postoperative change of the columellar labial angle was significantly smaller in the experimental group (−0.7°±1.16° vs. 2.2°±1.32°, P=0.015). The hybrid columellar strut showed superior postoperative nasal tip stability.

Conclusions We devised a new hybrid columellar strut and confirmed its superior mechanical firmness and stability. Considering the suggested indications and contraindications, the hybrid columellar strut graft can be a new modality for tip plasty in East Asian rhinoplasty that can provide sufficient long-term nasal tip stability.

Keywords East Asians / Maxillary bone / Ear cartilage / Rhinoplasty

Received: Jun 9, 2022 **Revised:** Oct 24, 2022 **Accepted:** Oct 25, 2022

Correspondence: Jin Woo Kim
Department of Plastic and Reconstructive Surgery, Inje University Busan Paik Hospital, Inje University College of Medicine, 75 Bokji-ro, Busanjin-gu, Busan 47392, Korea
E-mail: Jinooda@daum.net

INTRODUCTION

In modern rhinoplasty, nasal tip plasty is a crucial component for successful surgery outcomes from both functional and aesthetic perspectives [1]. Proper nasal tip projection and rotation are essential factors for an aesthetically pleasant nose, and the postoperative nasal tip is determined by the final position of the lower lateral cartilage [2].

As the lower lateral cartilage is a floating structure that is connected by many ligaments and fibrous tissues, dissection of the lower

lateral cartilage provokes instability of the nasal tip. Reinforcement of the weakened nasal tip support is necessary to accomplish and maintain the intended nasal tip shape after surgery [3].

If alar cartilage itself is strong enough, suture techniques alone could be used for nasal tip support [4]. However, East Asians usually have thicker skin and less developed lower lateral cartilage than Caucasians [5]. Because of these anatomical differences, using suture techniques alone is inappropriate to achieve and maintain proper tip projection in East Asians, unlike in Caucasians, whose alar cartilage is sufficiently strong and large [6].

Techniques such as the septal extension graft, columellar strut graft, and L-shaped alloplastic implants have been introduced for additional nasal tip support and projection [7]. However, delayed extrusion often occurs at the nasal tip when an L-shaped alloplastic implant is applied on the columellar strut because of excessive skin tension and pressure necrosis [8]. Several types of grafts using autologous cartilage, such as the double-layered conchal cartilage septal extension graft, double-layered septal cartilage columellar strut graft, double-layered conchal cartilage columellar strut graft, comma-shaped costal cartilage columellar strut graft, and L-shaped septal cartilage columellar strut graft have been introduced recently, but no consensus exists regarding the optimal method [3,5,6,9]. Furthermore, each extant autologous cartilage graft has drawbacks associated with its intrinsic strength, tendency of warping, and morbidity after the harvesting procedure. Based on our attempts to devise an autologous columellar strut graft without the drawbacks of preexisting materials, we suggest a hybrid columellar strut graft made of nasal crest bone of the maxilla and conchal cartilage for achieving nasal tip stability in rhinoplasty for East Asian patients.

METHODS

Patients

We analyzed 20 patients who underwent nasal tip plasty from May 2017 to June 2020. The inclusion criteria were East Asians (South Koreans) with no history of previous rhinoplasty, who were dissatisfied with their low nasal dorsum and tip and were willing to share their medical records and photographs for this study. The exclusion criteria were patients of other ethnicities and those with history of previous rhinoplasty, severe congenital anomalies on the nose, or a history of major trauma to the nose, as well as those who regarded individual privacy protection as a top priority. The inclusion and exclusion criteria were applied to select patients for nasal tip plasty in the outpatient clinic. We divided the subjects into two groups, which differed according to the material used in the columellar strut graft for nasal tip plasty.

The 20 study participants included 10 men and 10 women. To minimize bias due to structural differences between the sexes, the experimental and control groups were allocated in tens using stratified randomization in order to achieve an even sex ratio in both groups (5:5). The mean age of the patients in the control and experimental groups were 32.6 years and 35.2 years, respectively.

The 10 patients in the control group underwent surgery using conchal cartilage as a columellar strut. The other 10 patients in the experimental group underwent nasal tip plasty using a hybrid columellar strut made of nasal crest bone of the maxilla and ear cartilage.

In both groups, appropriate postoperative outcomes were obtained using operative techniques that were identical apart from the difference in the columellar strut graft. The follow-up period was up to 1 year after the operation. Preoperative, 1-month postoperative, and 1-year postoperative measurements of the nasal length, tip projection, and columellar labial angle of all subjects were performed, and the differences were statistically analyzed.

Surgical technique

All operations were open rhinoplasty via a columellar incision approach under general anesthesia or sedative anesthesia. A W-shaped incision was made across the columella at its narrowest point, and a consecutive marginal incision was made. The alar cartilage was dissected carefully with tenotomy scissors, avoiding any unintentional damage to the cartilage. Dissection and manipulation of upper lateral cartilage and nasal septum were minimally done unless there was septal deviation. Internal osteotomy was done if needed. The cymba concha was harvested from the front side of the ear in an oval shape. The length of harvested auricular cartilage was about 2 cm in each case. An ear molding prepared before surgery was used to prevent postoperative hematoma and to maintain the natural outline of the ear. An interdomal suture, a tip onlay graft, and a columellar strut graft were performed to define the nasal tip and achieve adequate tip projection and rotation.

In the control group, a fixed-type columellar strut graft was per-

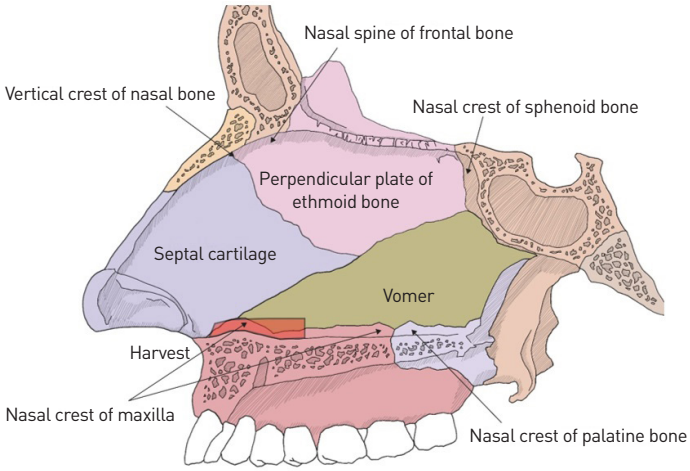

Fig. 1. Anatomical illustration of the nasal crest of the maxilla (the red zone is the harvest target).

formed with a symmetrically trimmed double layer of ear cartilage sutured together with Prolene 6-0 (Ethicon, Inc.). After placing a needle through the medial crura and a columellar strut graft with attention to symmetry, a medial crural fixation suture was done with Prolene 5-0 and the posterior end of the columellar strut graft was fixed to the anterior nasal spine with Prolene 5-0.

In the experimental group, the nasal crest bone of the maxilla was harvested with a Cottle elevator and osteotome through the endonasal approach (Fig. 1). The dimension was about 2.5×0.3 cm. The harvested bone was trimmed into a rectangular shape and then placed between two prepared conchal cartilages. After being tied together with Prolene 5-0 at the one-third and two-thirds points, the strut was placed between the medial crura (Fig. 2). The anterior end point of the strut was placed up to lobular segment of the middle crus, so that the domal segment of the middle crus could act as padding cartilaginous tissue to prevent a pressure sore of the nasal tip due to rigid end point of the strut. Two points of the medial crural fixation suture were made using Prolene 5-0 with a straightened needle in a penetrating manner, and one point of fixation to the anterior nasal spine was made with Prolene 5-0 (Fig. 3). Lastly, dorsal augmentation using an I-shaped silicone implant was performed in all patients. The lower end of the implant was suitably trimmed not to interfere with the nasal tip.

Cadaveric experiment

In a fresh cadaveric study of a 45-year-old female donor, we harvested the cymba concha and nasal crest bone of the maxilla. We planned to compare the mechanical strength of two autologous materials that could be used for columellar strut grafts against an external force in the same dimension: a hybrid columellar strut and a double-layered conchal cartilage columellar strut.

The nasal crest bone of the maxilla was trimmed to a rectangular shape (2.5×0.3 cm) and placed between two pieces of conchal cartilage (3.0×0.5 cm). Fixations were performed at the one-third and two-thirds points with Prolene 5-0. The measured dimensions of this hybrid autologous material were 3.0×0.5×0.3 cm. The double-layered conchal cartilage columellar strut was made in the same manner except for inserting the nasal crest bone fragment.

The two prepared strut graft materials were then grasped with large Kelly forceps at the one-third points. Next, 20-, 40-, and 60-g weights were connected by a thread on the contrary point, respectively. Therefore, sequential bending forces were applied to both materials. The vertical bending changes of each material due to the same external forces were observed.

Measurements

All patients had preoperative, 1-month postoperative, and 1-year postoperative photographs taken at the same distance (1.5 m). Nasal length was measured as the distance between the nasion and

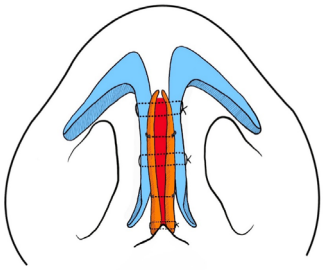

Fig. 3. Schematic illustration of the surgical technique. Red is the nasal crest bone of maxilla, orange denotes the auricular cartilage, and blue corresponds to the lower lateral cartilage.

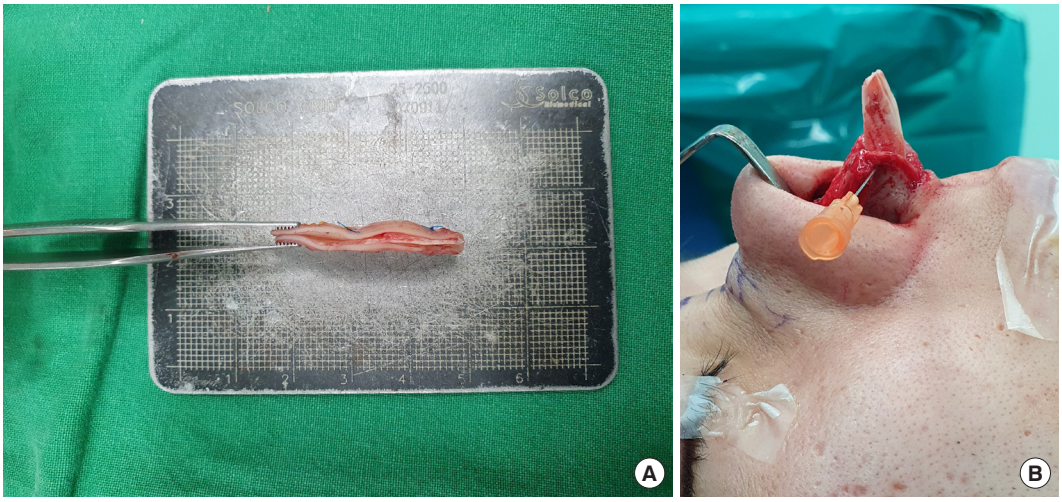

Fig. 2. Intraoperative pictures of hybrid columellar strut graft. (A) A hybrid columellar strut is made of nasal crest bone of maxilla between two pieces of conchal cartilage, and the two points were sutured with Prolene 5-0 for fixation. (B) The hybrid columellar strut is postioned for the proper nasal tip projection.

pronasale [10]. Tip projection was defined as the anteroposterior distance between the foremost point of the nasal tip and the most posterior point of the alar-facial junction [10]. Nasal length and tip projection were measured at an outpatient clinic preoperatively and postoperatively. The columellar labial angle, defined as the angle between the columella and the upper lip, was measured from the lateral view of the patient's photographs [10] (Fig. 4).

Statistics

SPSS version 25.0 for Windows (IBM Corp.) was used for analysis. After checking for normality of the data distribution, the anthropometric measurements of the two groups were compared using the Wilcoxon rank-sum test or the two-sample t-test in accordance with whether the requirement for normality was satisfied. Differences were considered statistically significant when the P-value was <0.05.

Survey

All patients were administered a survey about their satisfaction and surgical outcomes at a 1-year postoperative outpatient clinic visit. The questions about satisfaction consisted of three categories: satisfied, neutral, and dissatisfied. The question about surgical outcomes comprised one inquiry: whether the subjects recognized any postoperative change in their nose from 1 month to 1 year of follow-up.

RESULTS

Patients in both groups were discharged on postoperative days 5 to 7. All patients were asked to visit the outpatient clinic up to postoperative 1 year. As there were no cases of revision after surgery, patients' total follow-up period was standardized to 1 year according to the study design. There were no consultation requests from patients after the planned postoperative 1-year follow-up outpatient visit.

In the control group, the average nasal length was 4.70 ± 0.37 cm preoperatively, 5.02 ± 0.36 cm at 1 month postoperatively, and 4.99 ± 0.34 cm at 1 year postoperatively. The mean tip projection was 2.54 ± 0.41 cm preoperatively, 2.93 ± 0.36 cm at 1 month postoperatively, and 2.84 ± 0.39 cm in 1 year postoperatively. The mean columellar labial angle was 98.50° ± 4.84° preoperatively, 102.20° ± 6.30°

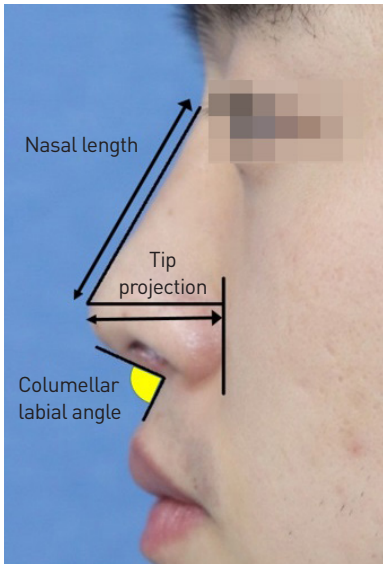

Fig. 4. Anthropometric measurements on a lateral-view photograph, showing the nasal length, tip projection, and columellar labial angle.

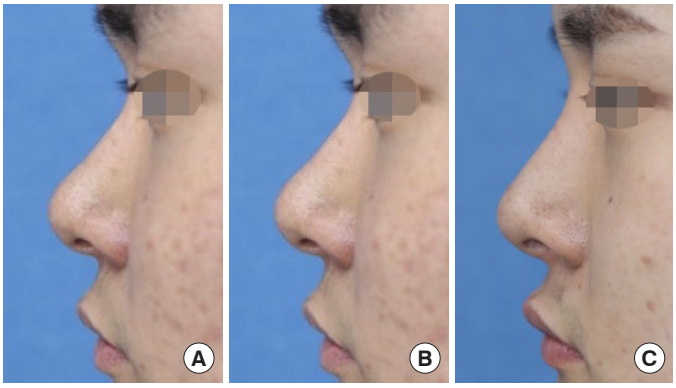

Fig. 6. Case of a 20-year-old male. (A) Preoperative photograph. (B) One-month postoperative photograph using double-layered conchal cartilage for the columellar strut graft. (C) One-year postoperative photograph using double-layered conchal cartilage for the columellar strut graft: a slight decrease in the columellar labial angle and mild columellar drooping were observed, and the outline of the columella became a bit more convex compared to the 1-month postoperative photograph.

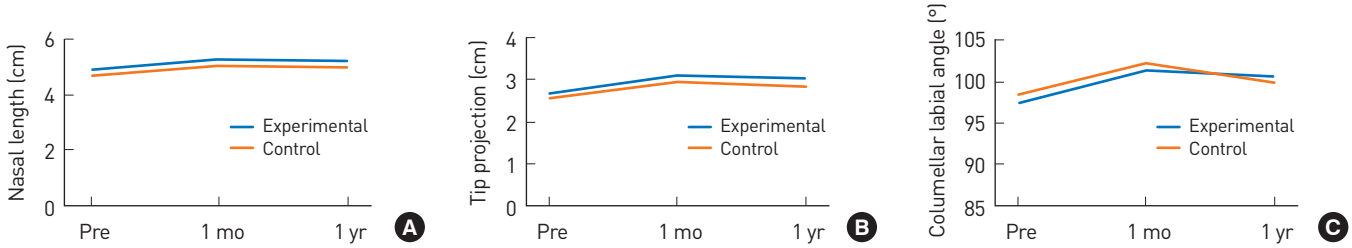

Fig. 5. Preoperative and postoperative in experimental and control groups. (A) Nasal length. (B) Tip projection. (C) Columellar labial angle.

at 1 month postoperatively, and 100.00°±5.58° at 1 year postoperatively (Figs. 5, 6).

In the experimental group, the average nasal length was 4.92±0.41 cm preoperatively, 5.26±0.32 cm at 1 month postoperatively, and 5.23±0.34 cm at 1 year postoperatively. The mean tip projection was 2.67±0.30 cm preoperatively, 3.09±0.30 cm at 1 month postoperatively, and 3.05±0.28 cm at 1 year postoperatively. The mean columellar labial angle was 97.50°±11.34° preoperatively, 101.40°±4.95° at 1 month postoperatively, and 100.70°±5.48° at 1 year postoperatively (Fig. 7).

As both groups contained 10 patients, we tested the normality of the distribution of analytical variables. Nasal length and tip projection did not satisfy normality; however, a normal distribution was confirmed for the columellar labial angle. Therefore, we performed the Wilcoxon rank-sum test for nasal length and tip projection variables and the two-sample t-test for the columellar labial angle variables. The P-values of postoperative changes between 1 month and 1 year for each measurement were as follows: nasal length, P=0.888; tip projection, P=0.074; and columellar labial angle, P=0.015. Only the postoperative change in the columellar labial angle showed a statistically significant difference (P=0.015) (Table 1).

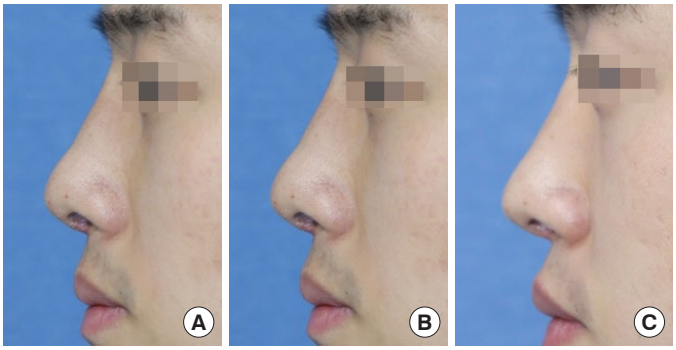

Fig. 7. Case of a 23-year-old male. (A) Preoperative photograph. (B) One-month postoperative photograph using a hybrid columellar strut graft. (C) One-year postoperative photograph using a hybrid columellar strut graft; no postoperative nasal tip change was observed at the 1-year follow-up.

In the experimental group, nine of 10 subjects were satisfied with their outcomes, and one was neutral. No patients answered that they were dissatisfied. None of the patients in the experimental group perceived recognizable postoperative changes between 1 month and 1 year (Table 2).

In the control group, seven patients were satisfied with their results, two patients were neutral, and one was dissatisfied. Seven of the 10 patients answered that they did not recognize any postoperative changes, postoperative nasal tip deviation was observed in one patient, and two patients showed slight nasal tip drooping combined with a hanging columella as a postoperative change from 1 month to 1 year. However, the two neutral patients and one dissatisfied responder stated that the degree of postoperative changes was minor and acceptable; therefore, none of the patients requested revision surgery. Over-rotation of the nasal tip or a "witch tip" was not observed in any patient. No patients complained of airway obstruction. Postoperative infection, seroma, extrusion, and skin necrosis were not observed in either group throughout the follow-up period.

Table 2. Satisfaction and patient-recognized postoperative changes in both groups

Variable	Experimental group	Control group
Patients' satisfaction		
Satisfied	9 (90)	7 (70)
Neutral	1 (10)	2 (20)
Dissatisfied	0	1 (10)
Patient-recognized postoperative changes[a]		
Not recognized	10 (100)	7 (70)
Deviation of tip	0	1 (10)
Drooping of tip	0	2 (20)

Values are presented as number (%). Experimental group: nasal tip plasty using a hybrid columellar strut made of nasal crest bone of the maxilla and ear cartilage; control group: surgery using conchal cartilage as a columellar strut.
[a]Patient-recognized postoperative changes between 1 month and 1 year.

Table 1. Anthropometric measurements

Variable	Experimental group			Control group			Postop change (1 yr–1 mo)		P-value
	Preop	1 mo postop	1 yr postop	Preop	1 mo postop	1 yr postop	Experimental group	Control group	
Nasal length (cm)	4.92±0.41	5.26±0.32	5.23±0.34	4.70±0.37	5.02±0.36	4.99±0.34	−0.03±0.05	−0.03±0.05	0.888[a]
Tip projection (cm)	2.67±0.30	3.09±0.30	3.05±0.28	2.54±0.41	2.93±0.36	2.84±0.39	−0.04±0.07	−0.09±0.06	0.074[a]
Columellar labial angle (°)	97.50±11.34	101.40±4.95	100.70±5.48	98.50±4.84	102.20±6.30	100.00±5.58	−0.70±1.16	−2.20±1.32	0.015[b]

Values are presented as mean±SD. Experimental group: nasal tip plasty using a hybrid columellar strut made of nasal crest bone of the maxilla and ear cartilage; control group: surgery using conchal cartilage as a columellar strut.
preop, preoperative; postop, postoperative.
[a]Wilcoxon rank-sum test; [b]Two-sample t-test. P<0.05 indicates a statistically significant difference.

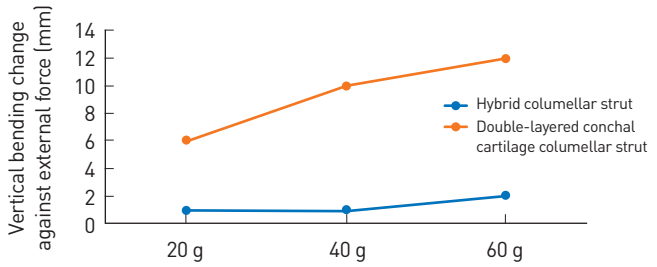

Fig. 8. The vertical bending changes of struts against external bending forces were measured.

Cadaveric experiment

In the hybrid material, there was a 1-mm vertical bending change when 20- and 40-g weights were applied, and a 2-mm vertical bending change a 60-g weight was applied.

In the double-layered conchal cartilage material, there were 6-, 10-, and 12-mm vertical bending changes in response to applying 20-, 40-, and 60-g weights.

We found that the hybrid material made of nasal crest bone of maxilla and two conchal cartilages has much stronger resistance against the same external force compared to double-layered conchal cartilage material in the same dimension (Fig. 8). This cadaveric experiment indicates that the mechanical firmness of the hybrid columellar strut graft we introduce in this study can offer sufficient supporting force to the nasal tip and is even stronger than the columellar strut only made of conchal cartilage.

DISCUSSION

Rhinoplasty is frequently performed among East Asians as cosmetic surgery. Compared to Caucasians, East Asians usually have a small, weak, and underdeveloped alar cartilage, so their dorsum and tip are low on average [5]. Thus, the goal of rhinoplasty in East Asian patients is usually focused on dorsum augmentation and tip projection rather than reduction. As the gap between the preoperative and postoperative state of nasal tip projection is larger, the postoperative counteracting contractile force on the skin enveloping the nasal tip is higher in East Asian patients after rhinoplasty [11]. Furthermore, East Asians tend to have thicker and inelastic skin [5,11]. Considering these factors, obtaining sufficient tip projection starting from a low and weak alar cartilage against a more resistive skin envelope is comparable to blowing up a small and thick rubber balloon to make it large. Even if surgeons achieve the intended nasal tip projection immediately after surgery, the continuous restoring force applied to the nose can gradually deform the nasal tip [11]. Occasionally, a postoperative change in the nose, such as tip deformity, or drooping, can lead to revision rhinoplasty [11]. Maintaining the same postoperative state in the long term is as important as achieving proper nasal shape immediately after surgery.

Achieving and maintaining the desired nasal tip is possible using solely suturing techniques when the alar cartilage is sufficiently large and strong [4]. Even if an additional supportive strut is needed, harvesting and using a small amount of septal cartilage is enough for Caucasians. When it is difficult to achieve the appropriate nasal projection with suturing techniques only, the septal extension graft, columellar strut graft, and L-shaped alloplastic implants have been used to provide additional support and projection for the nasal tip [7]. However, utilizing an L-shaped alloplastic implant for the nasal tip often leads to infection, delayed extrusion, and pressure skin necrosis of the tip [8]. Some cases of severe contracture after using an alloplastic implant applied on the nasal tip were also reported [12]. As a result, using only autologous graft materials for nasal tip plasty has been preferred to ensure safer outcomes [12].

To accomplish the desired results for patients and surgeons, Ghavami et al. [13] suggested a clinical algorithm for tip refinement and projection. In accordance with the algorithm, the columellar strut and medial crural suture play key roles in providing a stable and sturdy nasal base, especially in patients with thick-skinned noses [13]. Various autologous cartilage grafts, such as the double-layered conchal cartilage septal extension graft, double-layered septal cartilage columellar strut graft, double-layered conchal cartilage columellar strut graft, comma-shaped costal cartilage columellar strut graft, and L-shaped septal cartilage columellar strut graft, have been introduced for nasal tip plasty, but no consensus exists regarding the optimal method [3,5,6,9].

Conchal cartilage is known to be softer than other hyaline septal cartilage. Moreover, according to Rohrich's recent paper [14], a single columellar strut made of ear cartilage is not appropriate for adequate tip projection and precise tip rotation control. Several studies advocated the usefulness of the double-layered conchal cartilage columellar strut graft for nasal tip plasty [6,9]. However, postoperative changes, including a tendency for cephalic rotation of the nasal tip, were also reported in these studies [6,9].

Harvesting septal cartilage which is an invasive procedure, can cause septal weakness in East Asians, whose septal cartilage is usually smaller and thinner than that of Caucasians [15]. When the framework of the septal cartilage is damaged, it may even weaken the dorsal and caudal strut support, which can eventually result in tip projection decrease, tip distortion, and even nasal collapse [15]. Goudakos et al. [16] reported frequent cases of revision septoplasty due to septal deviation and nasal valve dysfunction after harvesting septal cartilage in cases of previous rhinoplasty. As secondary rhinoplasty cases are becoming more numerous in South Korea, it is important to preserve septal cartilage in a sound condition that can offer an additional choice of modality for revision procedures [11,15].

Costal cartilage is usually used for revision rhinoplasty due to its mechanical firmness, but it is also used for primary cases when there is a substantial gap between the preoperative state and postoperative goal for the patient's nose [17]. However, costal cartilage

is prone to gradually bending as time passes; this phenomenon, known as warping, often leads to severe postoperative nasal tip distortion [17]. Furthermore, costal cartilage harvesting is an invasive procedure that takes comparatively long time and requires careful attention, increasing the total operation time and the surgeon's fatigue [17]. Many studies have reported a positive correlation between the surgical time and complication rate [18]. Costal cartilage harvesting is also accompanied by donor-site morbidities such as pneumothorax, hemothorax, atelectasis, infection, seroma, visible chest scars, and chronic postoperative pain [19]. Despite their low incidence, acute morbidities (e.g., pneumothorax, hemothorax, and atelectasis) can be life-threatening when appropriate care fails [20]. For these reasons, some patients refuse to allow surgeons to use their costal cartilage [21].

From the standpoint of visible scars, the posterior approach for ear cartilage harvest is superior. However, the neurovascular system is distributed along the posterior surface of the ear, and it can be damaged when the posterior approach is performed [9]. We used an anterior approach with precise dissection of conchal cartilage and preservation of the perichondrium of the anterior skin flap. Careful dressing using a prepared ear molding was also performed. This prevented hematoma formation and maintained the outline and concavity of the ear. There were no donor ear site morbidities, such as a hypertrophic scar, contracture, or deformation of the ear, in any patients in our study.

According to the other study by Rohrich et al. [22], the added strength that the columellar strut provides for medial crural positioning contributes more than the length of the strut itself to nasal tip projection. Therefore, choosing an adequate columellar strut graft material for obtaining and maintaining long-term proper nasal tip projection is very important. However, the concha, septal, and costal cartilages all have their own shortcomings. Thus, we tried to identify an autologous graft material with superior supporting force and stability compared to the concha, septal, and costal cartilages that would not share their drawbacks. We made an osteochondral complex recombining the nasal crest of the maxilla and two conchal cartilages and used it as a hybrid columellar strut graft.

To demonstrate the mechanical strength of the hybrid columellar strut we devised, we performed a cadaveric study comparing the hybrid columellar strut to the double-layered conchal cartilage strut in the same dimensions. The mechanical strength of the hybrid columellar strut against the same bending force was much higher than that of the double-layered conchal cartilage strut. This finding implies the possibility of utilizing a hybrid columellar strut as an adequate autologous graft material for a higher nasal tip supporting force, as required for rhinoplasty in East Asian patients. In our comparative study of East Asian patients, postoperative columellar labial angle changes for a year were statistically significantly lower in the experimental group. This means that the hybrid columellar strut graft was superior to double-layered conchal cartilage columellar strut in maintaining the nasal tip support for 1 year postoperatively. These results confirm that the hybrid columellar strut graft has mechanical strength and superior stability for proper nasal tip projection and long-term maintenance in rhinoplasty in East Asian patients. Over-rotation of the nasal tip or a witch tip was not observed in any patient in the experimental group. Firstly, regarding the patient's preoperative nasal skin thickness and cartilage development, we refrained from pursuing excessive nasal tip projection due to the possibility of postoperative nasal tip deformation, including over-rotation or a witch tip. Secondly, as shown by the results of the cadaveric experiment, the hybrid columellar strut graft seems to provide superior mechanical rigidity to resist against the continuous restoring force applied to the nasal tip compared to the double-layered conchal cartilage columellar strut graft.

There are other advantages of using the hybrid columellar strut graft. Through the endonasal approach, we could harvest the nasal crest bone of the maxilla within 10 minutes from incision to mucosa repair without extension of the operation field. Especially when compared to harvesting costal cartilage, using the hybrid columellar strut drastically reduces the surgical time and restricts the operation field. Therefore, the potential hazard from prolonged general anesthesia and surgical site-related morbidity can be minimized by using the hybrid columellar strut graft [23]. According to our surgical procedure, septal cartilage harvest is not performed unless there is septal deviation. The nasal crest bone of the maxilla could be harvested through the endonasal approach without unnecessary dissection of the upper lateral cartilage and exposure of the caudal margin of septal cartilage. Thus, the integrity of the keystone area could be preserved as much as possible, thereby reducing the likelihood of an undesired postoperative nasal deformity. Preserving caudal septal cartilage is especially important for maintaining load-bearing tip support in East Asians, whose nasal septum is hypoplastic and thin [6,9].

For the reasons described above, we suggest the following indications and contraindications for using the hybrid columellar strut graft for East Asian rhinoplasty. If a patient complains of nasal airway obstruction and septal deviation is confirmed by preoperative facial computed tomography, septal cartilage harvesting would be a better choice for autologous cartilage material for both aesthetic and functional aspects than using a hybrid columellar strut [24]. Thus, the presence of a straight nasal septum without nasal airway problems can be the first indication for using a hybrid columellar strut for rhinoplasty. Virkkula et al. [25] reported that septal perforations were mainly attributed to postoperative complications of rhinoplasty using septal cartilage harvesting, and stated that it is difficult to restore septal perforation once it happens. Secondly, if an East Asian patient has weak cartilage and is concerned about this possible complication after septal cartilage harvesting, the surgeons could suggest using a hybrid columellar strut graft to provide a strong supporting force in nasal tip plasty. Revision rhinoplasty

cases are also becoming more common [11]; therefore, our technique could be recommended for patients undergoing primary rhinoplasty who are willing to preserve their septal cartilage as spare material for future occasions.

If a patient has a history of severe trauma or congenital anomaly (e.g., a palate malformation such as cleft palate), the nasal crest bone of the maxilla will not be straight or might even be absent. Therefore, a hybrid columellar strut in rhinoplasty is contraindicated in patients with these conditions. Furthermore, a hybrid columellar strut with harvesting of the nasal crest bone of the maxilla should not be performed in patients whose septal cartilage has already been resected and weakened. As recent studies have suggested that the caudal septum provides the majority of critical load-bearing tip support [6,9], damaging the integrity of the region below the caudal septal cartilage for patients with a history of septal cartilage harvest will further attenuate the postoperative nasal tip support.

As this study was confined to only 20 subjects and 1 year of postoperative observations, further studies among more patients and with longer-term follow-up would be necessary in the future. Subsequent studies should investigate whether resorption of the osteochondral complex occurs in the long term. Nasal tip stiffness and the possibility of breaking when the external force to the nasal tip exceeds the critical point are limitations. Columella widening after surgery also occurred, but as East Asians have congenitally undeveloped medial crura, the columella is usually narrow in the middle and short. From the aesthetic standpoint, a straightened lateral edge of the columella is thought to be better despite widening, and none of patients complained of this issue. Using a hybrid columellar strut in rhinoplasty of Caucasians or East Asians with well-developed medial crura may result in an excessively widened columella.

As East Asians generally have thick skin and a low nasal dorsum and tip due to less developed alar and septal cartilage compared to Caucasian noses, achieving and maintaining proper nasal tip projection in rhinoplasty for East Asian patients demands a strong graft material that can provide enough supporting force to the nasal tip. Many candidates for autologous graft materials have been introduced, with their own advantages and disadvantages, but no consensus yet exists regarding the optimal method. In this study we devised a hybrid columellar strut made of the nasal crest of the maxilla and conchal cartilage and confirmed its superior mechanical firmness and stability. Since it overcomes the disadvantages of preexisting modalities and provides long-term stability, this hybrid columellar strut graft may be a new modality for rhinoplasty in East Asian patients.

NOTES

Conflict of interest

No potential conflict of interest relevant to this article was reported.

Ethical approval

The study was approved by the Institutional Review Board of Busan Paik Hospital (IRB No. 2021-12-034-003) and performed in accordance with the principles of the Declaration of Helsinki.

Patient consent

The patients provided written informed consent for the publication and the use of their images.

ORCID

Jin Woo Kim https://orcid.org/0000-0002-7660-843X
Min Young Kim https://orcid.org/0000-0002-9507-8833
Dong Il Kim https://orcid.org/0000-0002-2116-2311
Jeong Hun Shin https://orcid.org/0000-0002-1643-7034

REFERENCES

1. Gruber RP, Weintraub J, Pomerantz J. Suture techniques for the nasal tip. Aesthet Surg J 2008;28:92-100.
2. Hussein WK, Ismail AS, Ibrahim AA, et al. Modified lateral crural spanning suture of the nasal tip: suspension element. Egypt J Ear Nose Throat Allied Sci 2017;18:5-10.
3. Dhong ES, Kim YJ, Suh MK. L-shaped columellar strut in East Asian nasal tip plasty. Arch Plast Surg 2013;40:616-20.
4. Pastorek N, Cleveland P. Improving projection of the nasal tip in primary endonasal rhinoplasty. Facial Plast Surg 2022;38:46-56.
5. Tae SP, Song JK, Ju HS, et al. Nasal tip plasty using a batten graft with ear cartilage in East Asians. Arch Aesthet Plast Surg 2016;22:57-62.
6. Suh YC, Jeong WS, Choi JW. Septum-based nasal tip plasty: a comparative study between septal extension graft and double-layered conchal cartilage extension graft. Plast Reconstr Surg 2018;141:49-56.
7. Lathif A, Alvarado R, Kondo M, et al. Columellar strut grafts versus septal extension grafts during rhinoplasty for airway function, patient satisfaction and tip support. J Plast Reconstr Aesthet Surg 2022;75:2352-8.
8. Graham BS, Thiringer JK, Barrett TL. Nasal tip ulceration from infection and extrusion of a nasal alloplastic implant. J Am Acad Dermatol 2001;44(2 Suppl):362-4.
9. Namgoong S, Kim S, Kim HR, et al. Folded cymba concha: is it large and stable enough for caudal septal extension graft in Asian rhinoplasty? Aesthet Surg J 2021;41:NP737-47.
10. Suhk J, Park J, Nguyen AH. Nasal analysis and anatomy: anthropometric proportional assessment in asians: aesthetic balance from forehead to chin, part i. Semin Plast Surg 2015;29:219-25.
11. Won TB, Jin HR. Revision rhinoplasty using autologous rib cartilage in Asians. Plast Aesthet Res 2019;6:6.
12. Kim YK, Kania K, Nguyen AH. Rhinoplasty with cartilage and alloplastic materials, nasal SMAS management in Asian rhinoplasty, contracture classification, and secondary rhinoplasty with contracture. Semin Plast Surg 2015;29:255-61.

13. Ghavami A, Janis JE, Acikel C, et al. Tip shaping in primary rhinoplasty: an algorithmic approach. Plast Reconstr Surg 2008;122:1229-41.
14. Rohrich RJ, Durand PD, Dayan E. Changing role of septal extension versus columellar grafts in modern rhinoplasty. Plast Reconstr Surg 2020;145:927e-931e.
15. Jeong JY. Obtaining maximal stability with a septal extension technique in East Asian rhinoplasty. Arch Plast Surg 2014;41:19-28.
16. Goudakos JK, Daskalakis D, Patel K. Revision rhinoplasty: retrospective chart review analysis of deformities and surgical maneuvers in patients with nasal airway obstruction: five years of experience. Facial Plast Surg 2017;33:334-8.
17. Kim JH, Song JW, Park SW, et al. 10th rib cartilage: another option of the costal cartilage graft for rhinoplasty. Arch Aesthetic Plast Surg 2015;21:47-53.
18. Porwal AC, Mathew BC, Abhishek P. Surgeon fatigue: a factor in intraoperative complications in high volume tertiary eye care center. Indian J Ophthalmol 2021;69:1634-35.
19. Kim T, Han J, Lee Y. Onlay rib bone graft in elevation of reconstructed auricle: 17 years of experience. Arch Plast Surg 2013;40:209-13.
20. McCarn KE, Weber SM. Ultrasonography for rapid detection of pneumothorax after costal cartilage harvest. Arch Facial Plast Surg 2011;13:57-9.
21. Rohrich RJ, Abraham J, Alleyne B, et al. Fresh frozen rib cartilage grafts in revision rhinoplasty: a 9-year experience. Plast Reconstr Surg 2022;150:58-62.
22. Rohrich RJ, Hoxworth RE, Kurkjian TJ. The role of the columellar strut in rhinoplasty: indications and rationale. Plast Reconstr Surg 2012;129:118e-125e.
23. Kim BD, Hsu WK, De Oliveira GS Jr, et al. Operative duration as an independent risk factor for postoperative complications in single-level lumbar fusion: an analysis of 4588 surgical cases. Spine (Phila Pa 1976) 2014;39:510-20.
24. Romo T 3rd, Kwak ES. Nasal grafts and implants in revision rhinoplasty. Facial Plast Surg Clin North Am 2006;14:373-87.
25. Virkkula P, Makitie AA, Vento SI. Surgical outcome and complications of nasal septal perforation repair with temporal fascia and periosteal grafts. Clin Med Insights Ear Nose Throat 2015;8:7-11.